

Introduction

Diabetic patients are vulnerable to microvascular and macrovascular disorders and retinopathy being one of them. Since diabetic retinopathy (DR) is a progressive disease, patients need to take retinal screening. Fundus cameras are widely used due to their portability and ease of use to capture the retinal images during the screening. Retinal digital imaging which is performed using fundus photography is an in-vivo technique that offers an inexpensive and non-invasive clinical assessment of retinal vascular topography and microvasculature including retinal vascular widths, geometrical attributes at vessel bifurcations and vessel tracking. Hence, retinal vasculature is a potential biomarker that would enable us to understand disease aetiology and progression among diabetic population.

Fundus imaging generates automate two-dimensional (2D) images of the interior three-dimensional (3D) of the retinal vasculature and that can be translated into quantitative values. Literature suggests that vascular changes are evident before the disease is diagnosed. A review conducted suggest that application of retina fundus camera imaging in dementia show inconsistent association between the two⁽¹⁾. This study aims to investigate whether retinal fundus photography imaging can predict dementia among the type 2 diabetic patients.

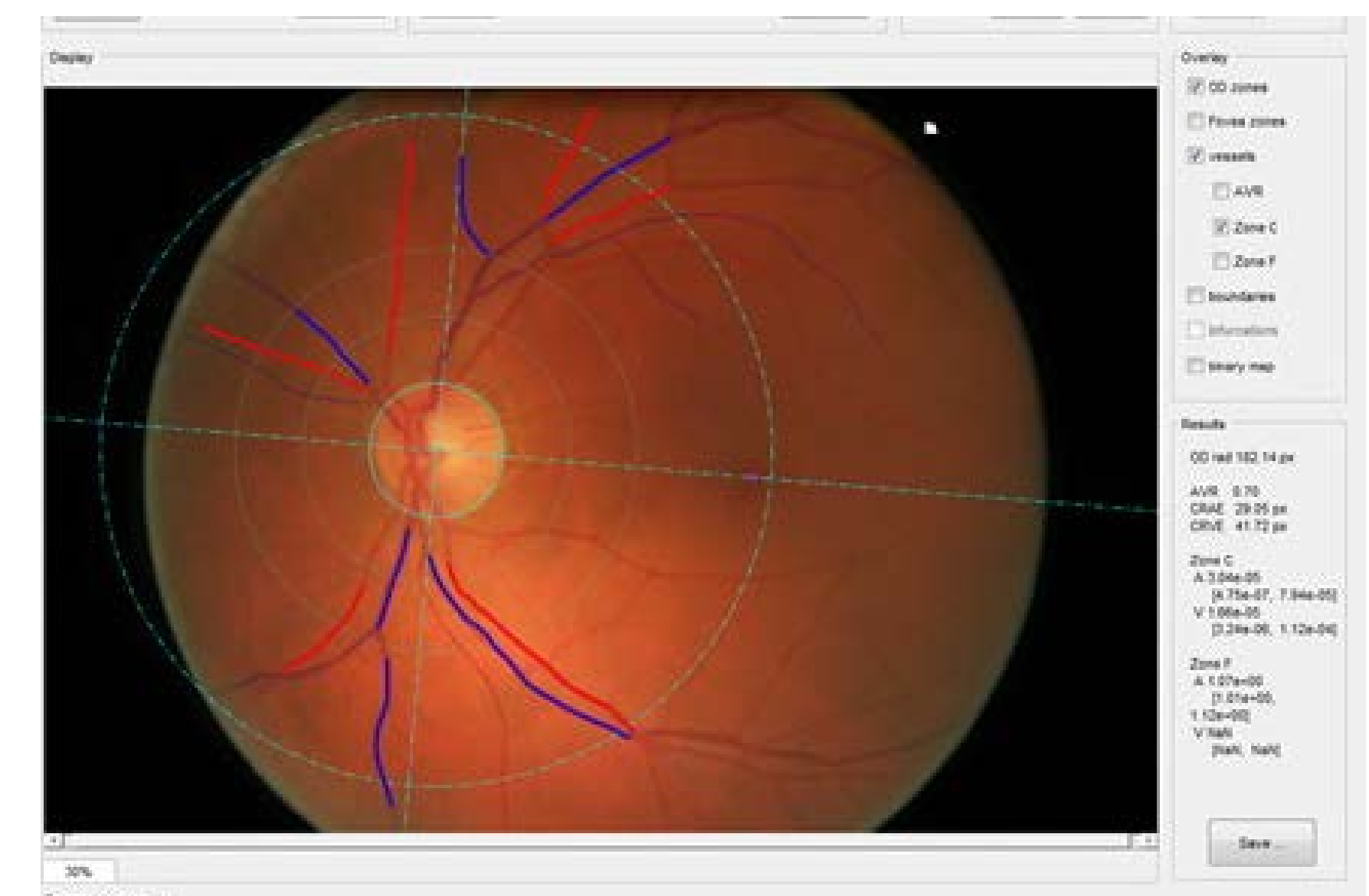
Methods

Participants were drawn from Genetic of Diabetes Audit and Research in Tayside Scotland (GoDARTS) who were reported to have type 2 diabetes. Electronic medical record linkage method was used to map patients which have been diagnosed with dementia. Patients with dementia were identified from routine data, based on ICD 10 and ICD 9 codes. Following datasets were merged for this purpose:

1. Scottish Morbidity Record for Hospital Admission (SMR01)
2. Scottish Morbidity Record for Psychiatry Admission (SMR04)
3. Community Prescribing Data
4. General Register's Office for Mortality Data (GRO)

Retinal image of total 4,500 patients have been recorded (fundus photograph) using VAMPIRE algorithm developed by School of Computing, University of Dundee, out of which 697 (15.49%) patients were known to have dementia. Retinal measurements like vessel width, fractal dimension and tortuosity of arterioles and venules were used in the study. Tortuosity and fractal dimensions measures were standardized and log-transformed to ease the comparison and satisfy normal distribution assumption.

Logistic regression with backward selection was performed to investigate whether retinal measurements can predict dementia outcome adjusted for age and gender. The best fit model was selected using Akaike Information Criterion (AIC).



S Mcgrory et al. Towards Standardization of Quantitative Retinal Vascular Parameters: Comparison of SIVA and VAMPIRE Measurements in the Lothian Birth Cohort 1936; Translation Vision Science and Technology; 2018

Results

From **Table 1**, mean age of the participants is 77.15 years (± 11.01 SD) and 697 (15.49%) are estimated to have all types of dementia. Patients with dementia are older compared to no dementia and females are reported have dementia in the cohort. The mean measurements of the retinal features which include arterial and venule vessel width and tortuosity do not show much difference. Further, mean measurement of arterial and venule fractal dimensions show difference, but it is negligible.

Table 1: Demographics of the cohort

| Variable | Dementia | No Dementia |
|--------------------------------|----------------------|------------------------|
| All patients (n=4500) | 697 (15.49%) | 3803 (84.51%) |
| Females (n=2406, 53%) | 363 (15.09%) | 2043 (84.91%) |
| Age (Mean, in years) | 84.61 (± 7.58) | 75.78 (± 10.99) |
| Retinal Features | | |
| Arterial Vessel Width (pixels) | 32.12 (± 2.96) | 32.43 (± 2.89) |
| Venule Vessel Width (pixels) | 42.37 (± 3.72) | 42.79 (± 3.66) |
| Arterial Fractal Dimension* | 0.02 (± 1.04) | -0.003 (± 0.99) |
| Venule Fractal Dimension* | 0.002 (± 0.99) | -0.0003 (± 1.00) |
| Arterial Tortuosity | -9.84 (± 0.99) | -9.78 (± 1.00) |
| Venule Tortuosity* | -9.68 (± 0.78) | -9.67 (± 0.77) |

*50 AFD measurements are missing; 61 VFD measurements are missing; 1 VT measurement is missing. Mean(\pm SD); n(%)

Table 2: Logistic regression association between dementia and retinal features

| Variable | All Dementia | | |
|------------------------------|--------------------------------------|---|-----------------------------------|
| | Un-adjusted (n=4,500) OR (95% CI) | Fully Adjusted (n=4,419) OR (95% CI) | Selected (n=4,450) OR (95% CI) |
| Vessel Width (Arterial) | 0.96 (0.93-0.99) | 0.94 (0.91-0.98) | 0.94 (0.91-0.98) |
| Vessel Width (Venule) | 0.96 (0.94-0.99) | 0.99 (0.96-1.02) | - |
| Fractal Dimension (Arterial) | 1.02 (0.94-1.11) | 1.09 (0.99-1.21) | 1.09 (0.99-1.21) [#] |
| Fractal Dimension (Venule) | 1.00 (0.92-1.08) | 1.05 (0.95-1.16) | - |
| Tortuosity (Arterial) | 0.94 (0.86-1.01) | 1.00 (0.91-1.08) | - |
| Tortuosity (Venule) | 0.98 (0.89-1.09) | 1.02 (0.91-1.13) | - |
| Age | 1.10 (1.09-1.11) | 1.10 (1.09-1.11) | 1.10 (1.09-1.11) |
| Gender | 1.09 (0.93-1.28) | 1.00 (0.87-1.23) | - |

[#]Marginal significant, p<0.1

From the **Table 2**, logistic regression with backward selection shows arterial and venule vessel width do not show risk for all types of dementia (outcome variable) [OR=0.95 (CI:0.91-0.98)] and age shows significant risk factor [OR=1.10 (CI:1.09-1.11)]. In the selected logistic model, variables including venule vessel width, fractal dimensions of both arterial and venule, gender and diabetes status were also included, but these variables did not show significant odds ratio; however this model showed lowest AIC hence, these variables might be good predictor of all of types of dementia.

Conclusions

According to the review conducted by S Mcgrory et al⁽¹⁾ association between retinal features and dementia is inconsistent and our analysis is in concordant with this review. However, changes in fractal dimension of arterioles indicate marginal risk for all types of dementia and age shows significant risk factor and changes in arterial and venule vessel width is not a risk factor for all types of dementia. Further investigation is required to examine arterial vessel width as to why it is a protective factor in our cohort.

Reference

1. S. Mcgrory, J. Cameron et al; *The application of retinal fundus camera imaging in dementia: A systematic review*; Alzheimer's & Dementia: Diagnosis, Assessment & Disease Monitoring; 6 (2017) 91-107.

Acknowledgements

We are grateful to the participants and team members of GoDARTS study and VAMPIRE group at School of Computing, University of Dundee. We would like to thank Dr. Shona Matthew for her valuable feedback.

The research was commissioned by the National Institute for Health Research using Official Development Assistance (ODA) funding [INSPIRED 16/136/102].

Disclaimer: "The views expressed are those of the author(s) and not necessarily those of the NHS, the NIHR or the Department of Health and Social Care."